

The logo for the Leipzig Interventional Course (LINC) features the letters 'LINC' in a white, sans-serif font. To the right of the text is a stylized graphic consisting of two overlapping, curved shapes in red and orange, resembling a flame or a dynamic motion. The entire logo is set against a dark blue background with a subtle, larger-scale brushstroke pattern.

LINC

Leipzig Interventional Course
January 22 – 25, 2019

**Bi-directional, self-expanding stent for
superficial femoral artery lesions –
2-year interim-results from the Q3 registry**

Hans Krankenberg

on behalf of the Q3-Investigators

Department of Angiology, Asklepios Klinikum Harburg
Hamburg, Germany

Disclosure

Speaker name: Hans Krankenberg

I have the following potential conflicts of interest to report.

- **Speakers fee:** QualiMed Medizinprodukte, Wedel, Germany


Q3 registry

Q3-Investigators

- Hans Krankenberg, Hamburg
- Jarwed Arjumand, Christian Jacke, Gabriela Marin, Wuppertal
- Gunnar Tepe, Rosenheim
- Erwin Blessing, Karlsbad
- Markus Spanagel, Achmet Mechmet, Eric Ipcsics, Waldbröl
- Viktor Reichert, Sindelfingen
- Stefan Betge, Bad Bevensen
- Ralph Wickenhöfer, Thorsten Kanis, Dernbach
- Jörg Teßarek, Lingen

Bi-directional SFA stent*

- Self-expanding Nitinolstent, laser-cut
- Wave-like segments with flexible connectors
- 8 Tantalum markers
- Delivery catheter is operable by one hand
- 5-zone flexibility delivery catheter



Designed to resist „bi-directional torsion“.

* QualiMed Medizinprodukte, Wedel, Hamburg; Germany

Q3 Registry

Patient Characteristics

N = 199 (Dec 2014 – Aug 2018)

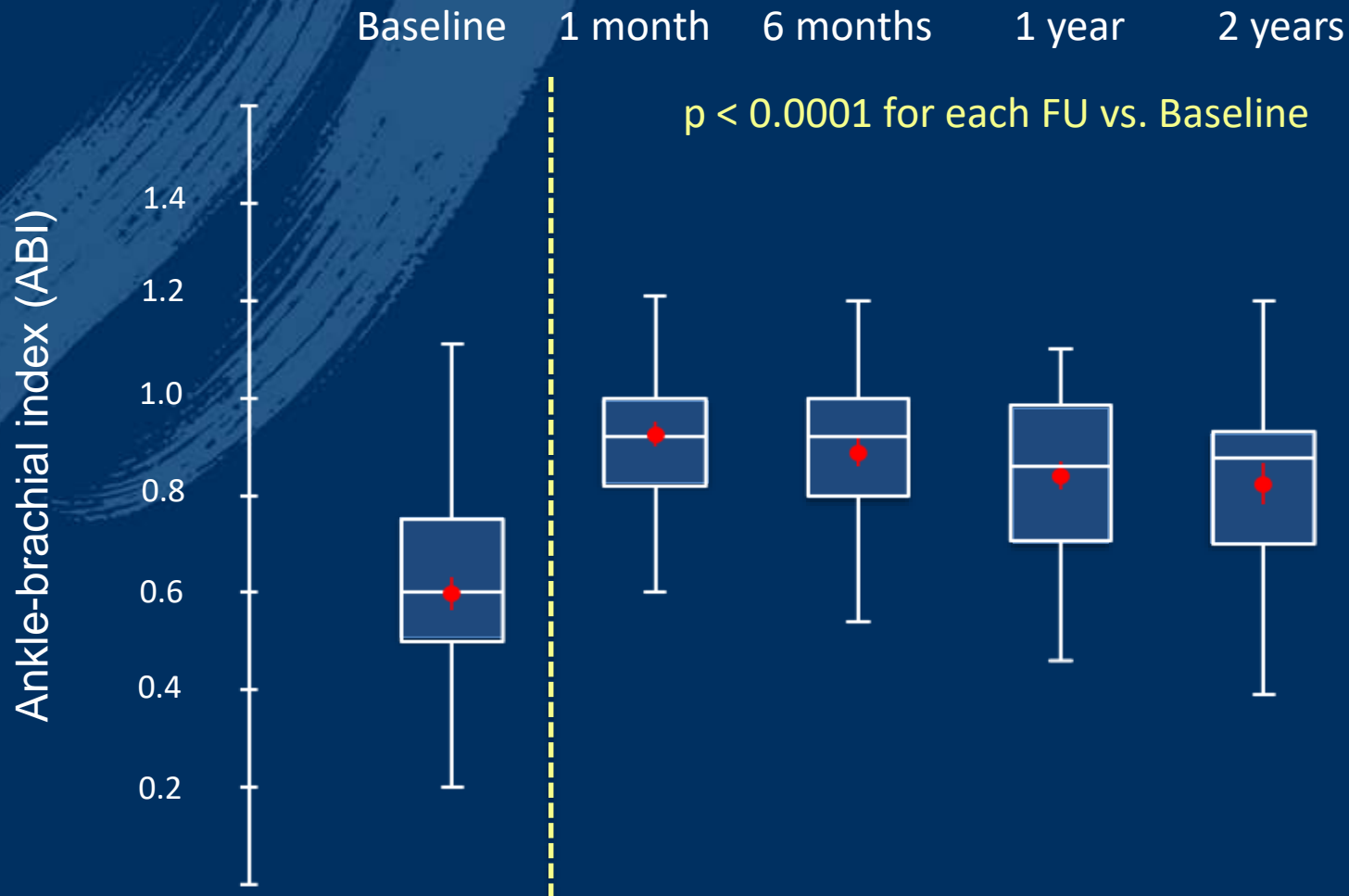
Age, yrs	60.3 ± 9.1
Male	70.4%
Diabetes mellitus	37.2%
Hypertension	83.8%
Hyperlipidemia	69.8%
Renal insufficiency	11.8%
Smoker (current and former)	52.6%
Adipositas	23.6%
Critical ischemia	11.6%
ABI	0.60 ± 0.24

Q3 Registry

Lesion Characteristics

Lesion length	97.6 ± 83.4 mm
Lesions ≥ 150 mm	23.5%
Stents/lesion	1.4 ± 0.7
Stented length	114.3 ± 82.7 mm
% Diameter stenosis	91.2 ± 13.1%
Total occlusion	43.5%
PTA Restenosis	3.0%
Multifocal or diffuse pattern	47.6%
Heavy calcification	27.3%

Hemodynamic Improvement



Hemodynamic improvement
by ≥ 0.15 or to ≥ 0.9

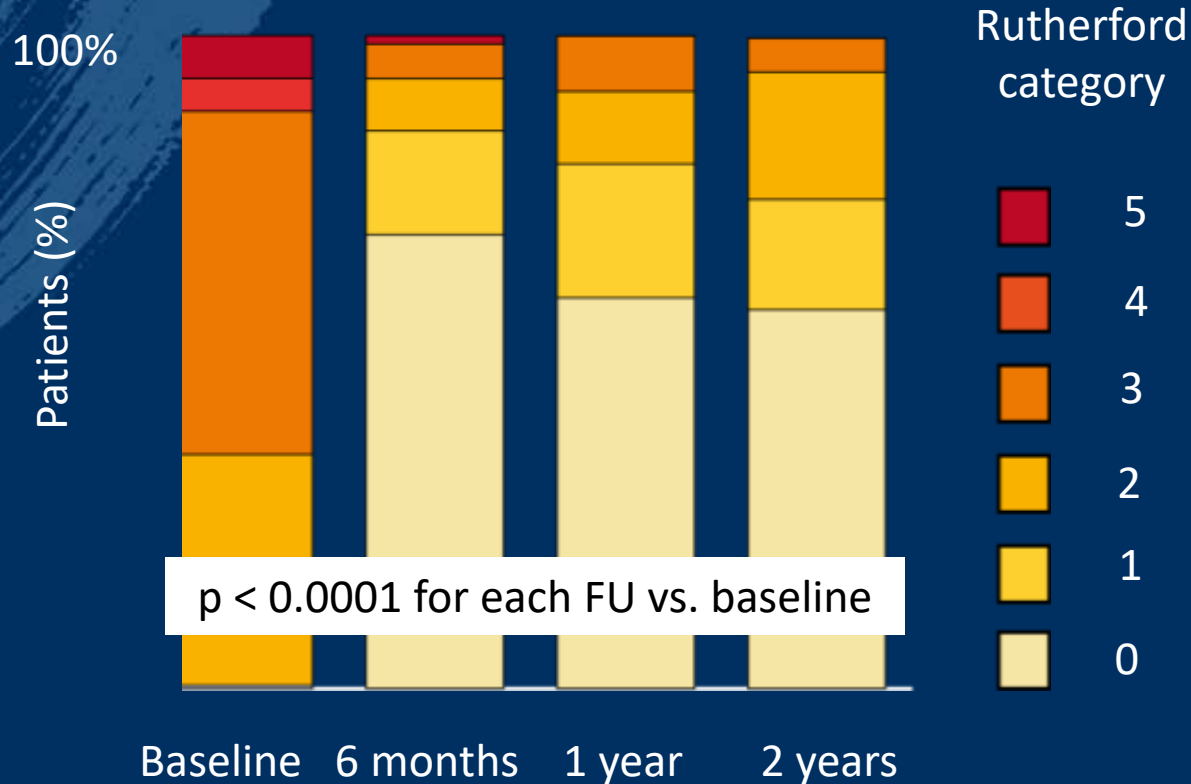
92.1%
n=165

76.2%
n=143

71.0%
n=107

73.6%
n=47

Clinical Improvement



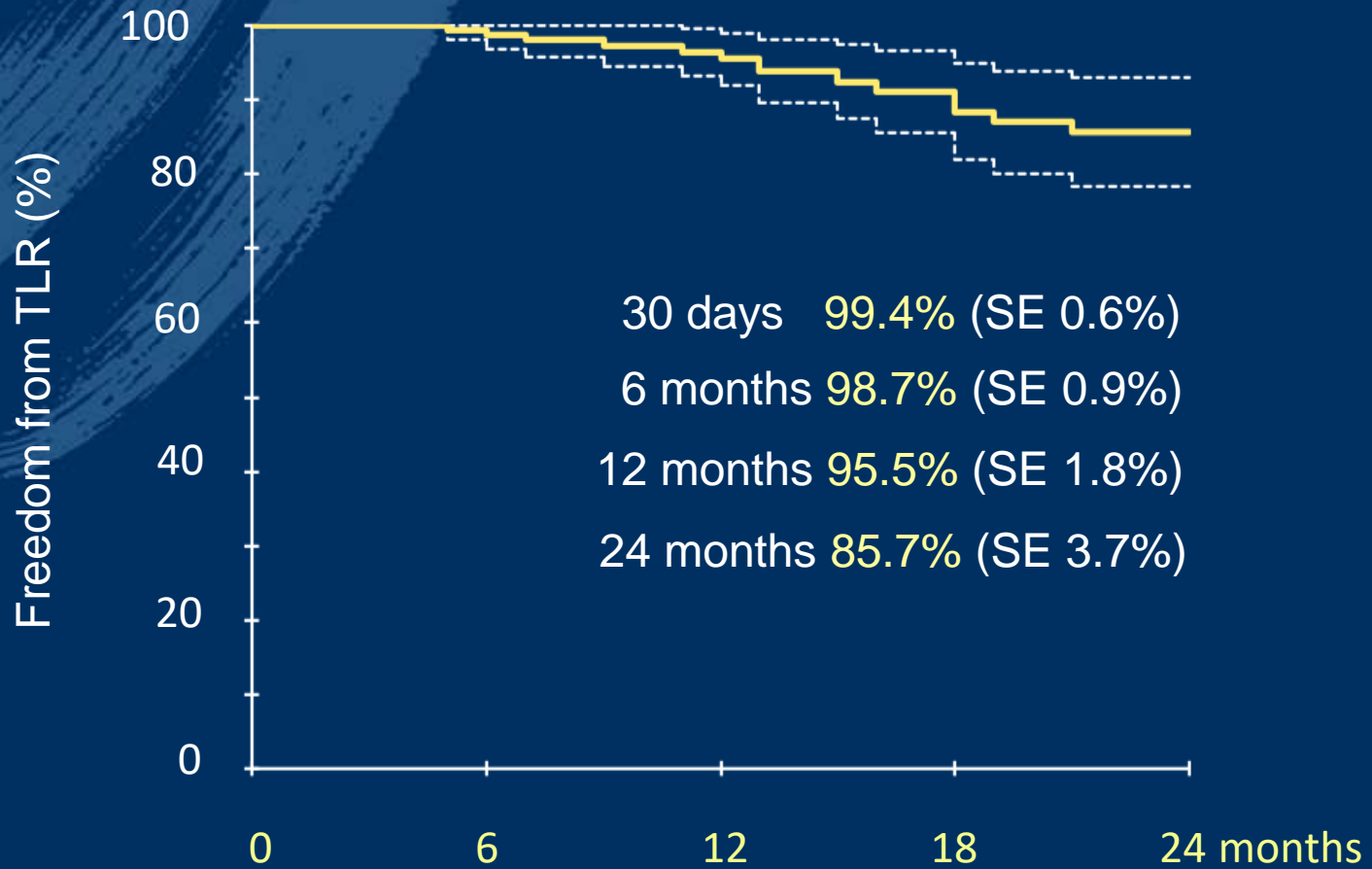
Clinical improvement
by ≥ 1 Rutherford category

92.1%
n=151

92.2%
n=115

92.3%
n=78

Freedom from TLR



Patients at risk

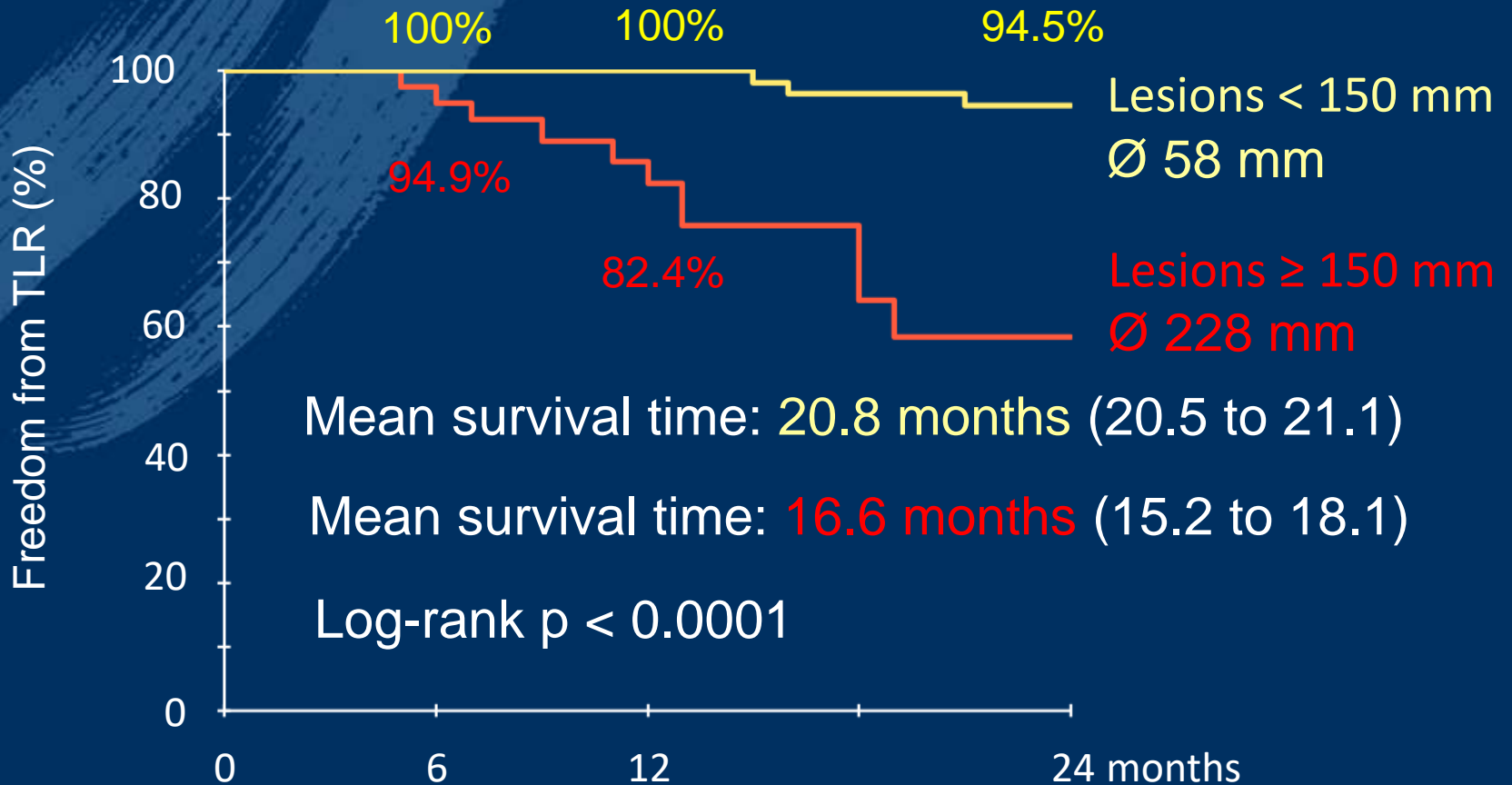
199

152

114

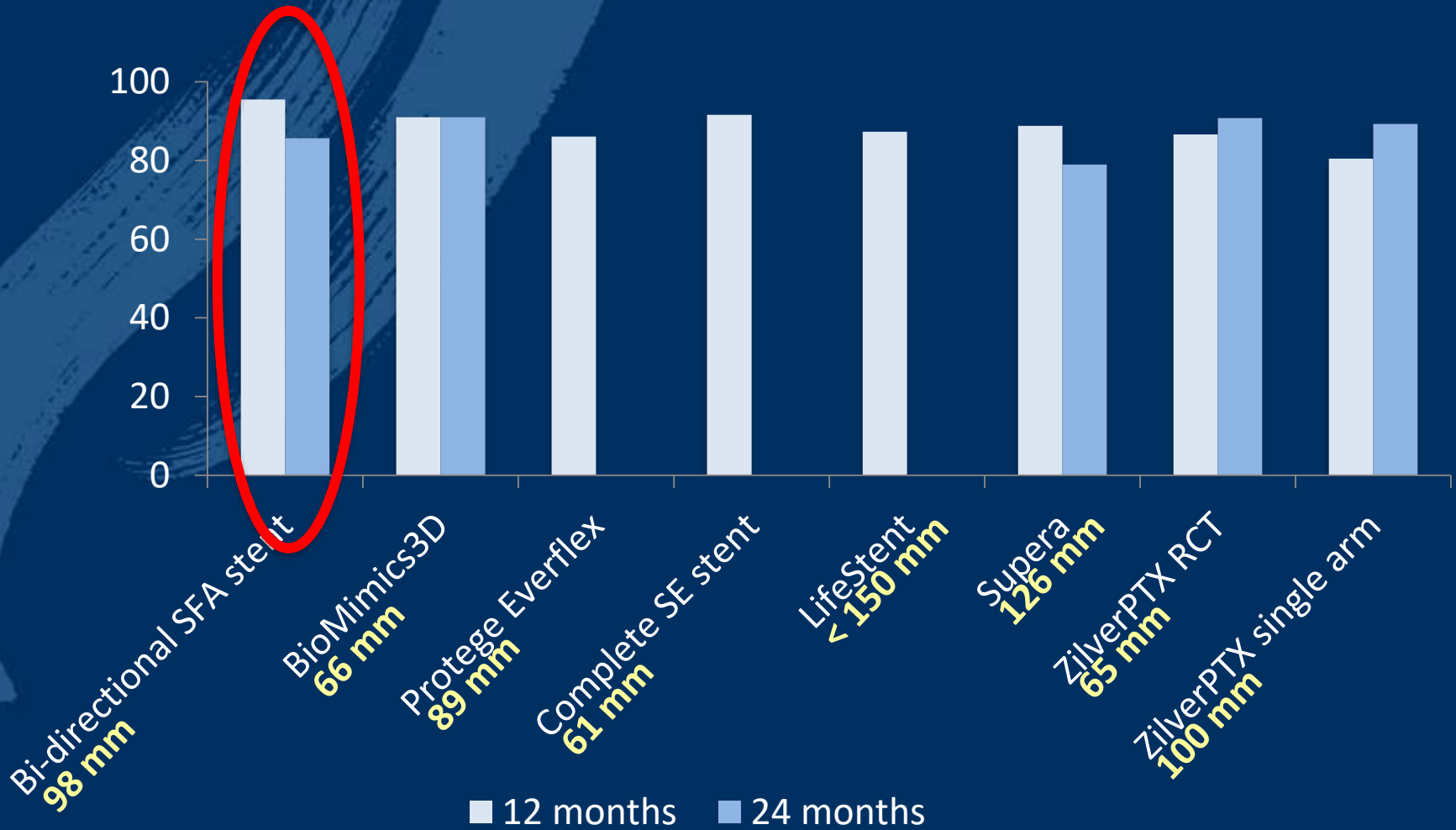
63

Freedom from TLR



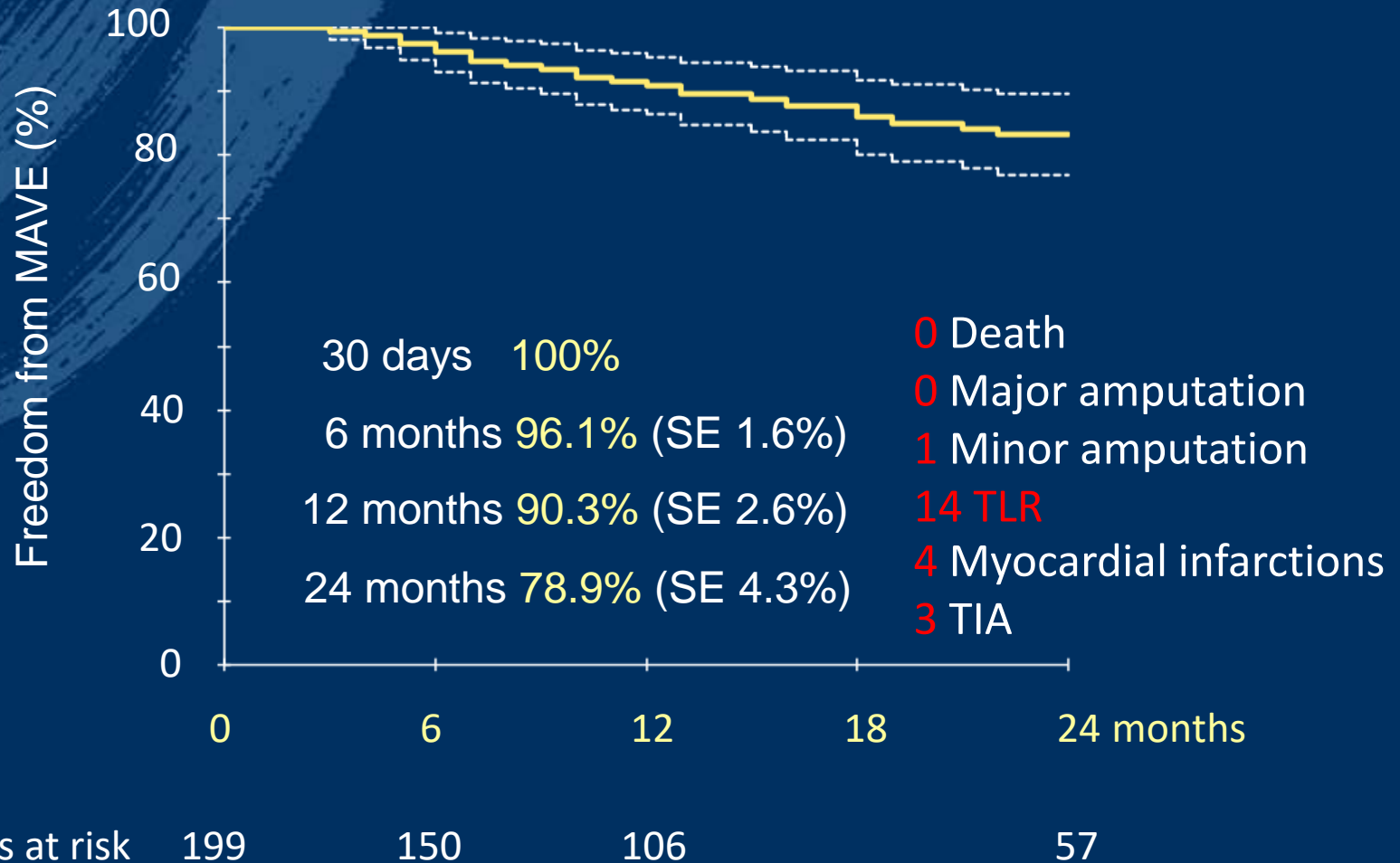
Patients at risk	150	112	85	52
	46	38	26	10

Freedom from TLR



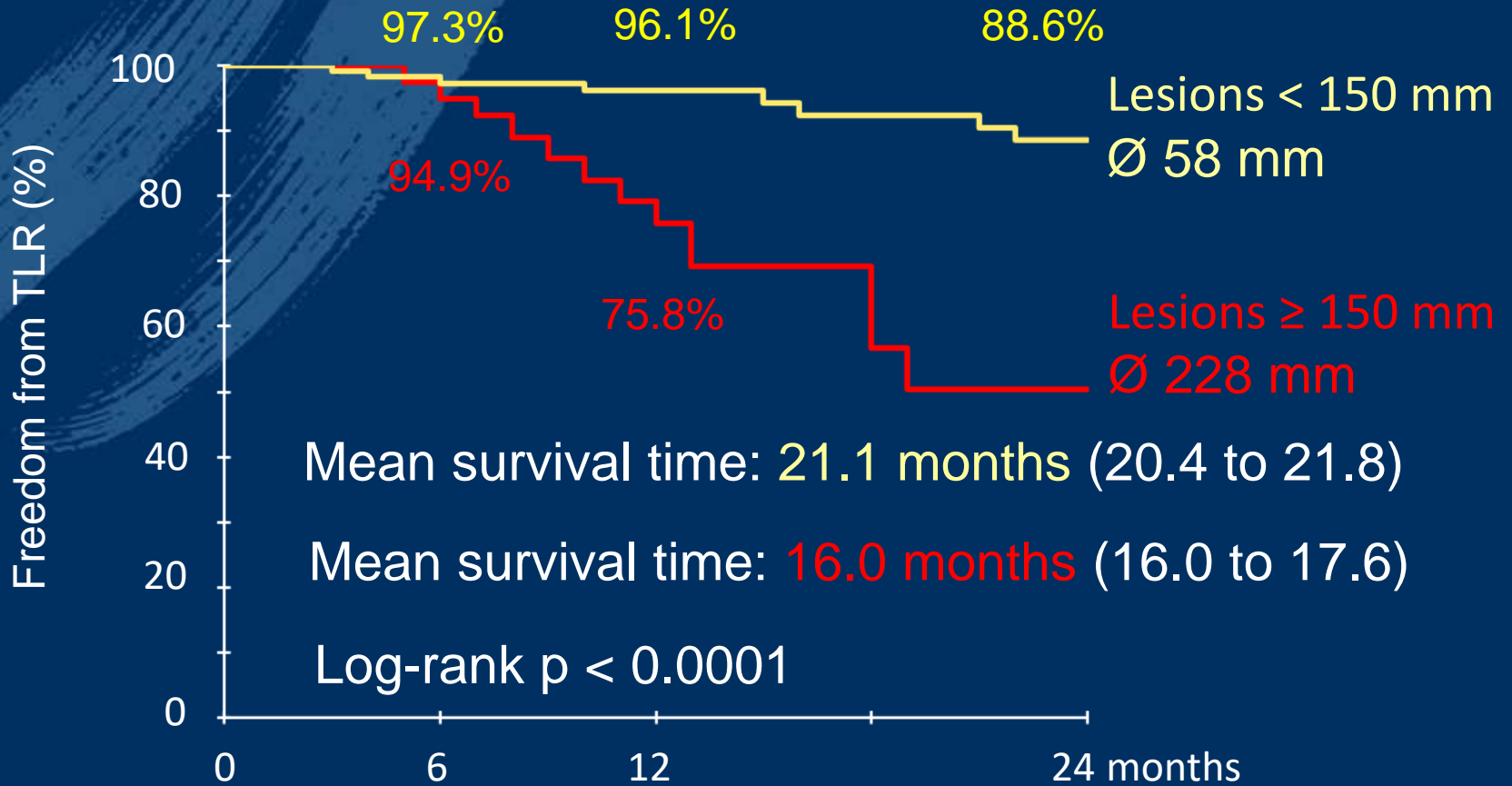
Zeller 2016, Matsumura 2013, Laird 2014, Laird 2012, Werner 2014, Dake 2013

Freedom from MACLE*



* CV death, MI, stroke, TIA, target limb minor or major amputation, bypass surgery, TLR

Freedom from MACLE



Patients at risk	150	110	82	47
	46	38	24	8

Conclusion

Interim analysis suggests a comparatively high effectiveness of the bi-directional SFA stent.

It did not raise any safety concerns.

**Bi-directional, self-expanding stent for
superficial femoral artery lesions –
2-year interim-results from the Q3 registry**

Hans Krankenberg

h.krankenberg@asklepios.com